

Tibial Plateau Leveling Osteotomy (TPLO)

Treatment for Cranial Cruciate Ligament Rupture

The most common cause for lameness in the hind limb of a dog is rupture of the cranial cruciate ligament (also referred to as the anterior cruciate ligament, or ACL). This injury in the knee results in chronic lameness and progressive degenerative changes including osteoarthritis, cartilage damage and meniscal injury. Early surgical intervention can return the knee to full function and minimize degenerative changes.

BIOMECHANICS ♦ The cranial cruciate ligament is an essential component for stabilization of the canine knee. Unlike humans, a dog's cranial cruciate ligament is under constant stress during not only physical activity but also at a normal resting stance. This difference is caused by the fact dog's stand on their toes with their heel elevated off the ground and knee in flexion [Figure 1]. The weight bearing surface of the tibia (tibial plateau) is sloped and the dog's hind limb posture causes the femur to be pushed backwards down the sloped tibial plateau, forcing the tibia forward. This force is primarily opposed by the cranial cruciate ligament. Over time constant stresses on the cranial cruciate ligament cause microscopic degeneration of the ligament eventually resulting in rupture [Figure 2]. Factors commonly contributing to cruciate ligament rupture may include a steep tibial slope, strenuous activity, poor body conditioning, obesity, or age.

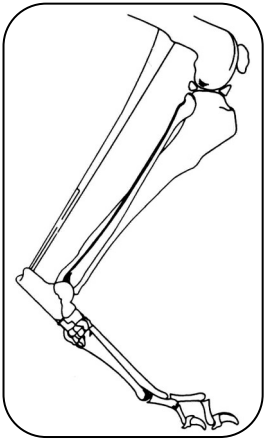


Figure 1

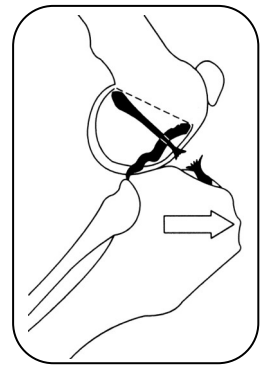


Figure 2

TPLO SURGERY ♦ Tibial Plateau Leveling Osteotomy is a very effective procedure in all breeds but is most applicable in large, active dogs due to the inherent structural stability it provides. The TPLO procedure corrects excessive tibial plateau slope by surgically cutting the upper tibia and rotating the weight bearing tibial surface. A bone plate designed specifically for this procedure is applied across the bone cut, or osteotomy, to allow for bone healing [Figure 3]. By leveling the tibial plateau, the forward force of the tibia and the "down hill" movement of the femur are neutralized. The TPLO technique eliminates the requirement to replace the ruptured cruciate ligament as a restraint against forward tibial force. Other concurrent injuries to structures in the knee, commonly meniscal tears, are evaluated and corrected as needed during surgery.

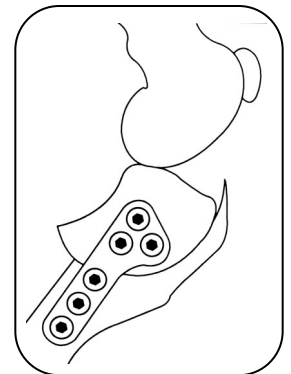


Figure 3

POSTOPERATIVE CARE ♦ Recovery may take three to four months. Bone healing is usually complete by 8 to 10 weeks, confirmed by radiographs of the knee. Initial management consists of immobilization with a bandage for a week followed by leash-quality activity for 6 weeks. Controlled activity is allowed in two months and full activity in three to four months. Most dogs return to hunting, field trials or competition within six months.

All Pets 
Veterinary Hospital
28326 S. Western Avenue
Rancho Palos Verdes, CA
310-547-2784